

Case report of unusual presentation of marfanoid features in a 13-year-old boy with Gardner's syndrome

Osama Abdalla Mabrouk Kheiralla¹, Abdullah I Aedh², Waleed G Babikr², Madani MA Globawe²

¹Department of Radiology, Faculty of Medicine, University of Najran, Najran, Saudi Arabia.

²Department of Internal Medicine, Faculty of Medicine, University of Najran, Najran, Saudi Arabia.

Correspondence to: Osama Abdalla Mabrouk Kheiralla, E-mail: drkheiralla@gmail.com

Received December 10, 2015. Accepted January 6, 2016

Abstract

Gardner's syndrome is a rare syndrome with autosomal dominant inheritance composed of a group of colonic and extracolonic disorders. Colonic disorders include intestinal polyps mainly adenomas, and extracolonic disorders include desmoid tumors, epidermoid cysts, and osteomas. Here, we present a 13-year-old boy, who was confirmed with Gardner's syndrome; but, when we did physical examination, he revealed unusual extracolonic findings similar to that in Marfan syndrome, raising suspicion that the genetic mutation on the long arm of chromosome 5, which is responsible for Gardner's syndrome, may also lead to some marfanoid abnormalities. Patients with Gardner's syndrome may present at any age from early months of life up to late years. They have high probability of developing colonic cancer, because of colonic polyps that undergo malignant transformation, but, fortunately, colonic polyps show up late in life beyond other extracolonic disorders such as bone osteomas and desmoid tumors. This feature gives the chance for early diagnosis of patients with Gardner's syndrome and allows undergoing early prophylactic surgical resection of polyps before transformation into malignant tumors.

KEY WORDS: Gardner syndrome, familial adenomatous polyposis (FAP), Marfan syndrome, desmoid tumor, epidermoid cysts

Introduction

Familial adenomatous polyposis (FAP) is an autosomal dominant disorder characterized by the development of multiple adenomas in the colon and rectum and a high risk of subsequent cancer. There is a relation with numerous extraintestinal manifestations, which include osteomas, epidermoid cysts, and desmoid tumors. These were first described by Gardner and colleagues (Gardner and Plenk 1952; Garner and Richards 1953; and Gardner 1962), and the combination of colorectal polyposis and these other features is referred to as Gardner's syndrome.^[1]

Gardner's syndrome is an autosomal dominant disorder and a subtype of FAP. It is designated by adenomatous intestinal polyps, multiple osteomas in the skull, maxillae, mandible, and multiple cutaneous and subcutaneous masses (epidermoids and desmoid). Intestinal polyps, if not treated, have 100% chance of becoming malignant.^[2] Gardner's syndrome is believed to occur owing to mutation in a gene located on chromosome 5 (5q21-22) known as adenomatous polyposis coli (APC) tumor suppressor gene, which is strongly linked to extracolonic manifestations. In 1991, the APC gene (chromosome 5q21-22) was identified and found to be mutated in FAP patients.^[3,4] Hereditary disorders of the connective tissue include a broad spectrum of skeletal, ocular, and cardiac abnormalities ranging from very mild conditions to the most severe Marfan syndrome (MFS).^[5,6] Molecular analysis of Marfan-like conditions has unveiled that patients with congenital contractural arachnodactyly (CCA or Beals syndrome) carry germline mutations of the fibrillin 2 (FBN2) gene on chromosome 5q23–q31.^[5,7] Despite, most of the cases occur owing to familial clustering; about 30% may occur owing to mutations. It is believed that the pathogenesis of Gardner may be owing to environmental factors such as smoking and dietary habits.

Access this article online

Website: <http://www.ijmsph.com>

DOI: 10.5455/ijmsph.2016.10122015305

Quick Response Code:



International Journal of Medical Science and Public Health Online 2016. © 2016 Osama Abdalla Mabrouk Kheiralla. This is an Open Access article distributed under the terms of the Creative Commons Attribution 4.0 International License (<http://creativecommons.org/licenses/by/4.0/>), allowing third parties to copy and redistribute the material in any medium or format and to remix, transform, and build upon the material for any purpose, even commercially, provided the original work is properly cited and states its license.

Symptoms of Gardner's syndrome can present at any age from 2 months to 70 years. The clinical presentation of Gardner's syndrome is variable, and its diagnosis is often delayed, despite the presence of clues for a significant amount of time. Because Gardner syndrome may include different organs, it is generally very tough to treat it, and the therapeutical effect is also doubtful.^[8] Osteomas are the most common skeletal abnormalities and fundamental for diagnosis of Gardner's syndrome; they generally present in early years of life either as exostoses peripherally or enostoses. They are characteristically located in the mandible and more precisely in the angle of the mandible, which represent a diagnostic location for Gardner. Presence of osteomas is required to make the diagnosis of Gardner's syndrome. The mandible is the most common location; however, osteomas may occur in the skull, paranasal sinuses, and the long bones.^[2,9] Osteomas appear radiologically as a radiopaque bony lesion with smooth surface. Dental anomalies as odontomas, and supernumerary, impacted, and unerupted teeth may be seen in about one-third of patients with Gardner, their incidence is highly associated with multiple osteomas. Intestinal polyps show up around the fourth decade of life; they may affect any part of the gastrointestinal tract and show a high probability for malignant transformation. Epidermoid cysts are the basic cutaneous lesion in Gardner, representing about 50% of clinical presentation mainly in the face and scalp. Desmoid tumors are less common and may be seen in the anterior abdominal wall. The epidermoid cyst, the most common cutaneous finding in Gardner's syndrome, is present in multiple forms in 50%–60% of the patients and may occur on the face, extremities, and/or the scalp.^[10] Other abnormalities detected in Gardner's syndrome include hyperpigmentation of retinal epithelium and papillary carcinoma of the thyroid. Ophthalmic examinations were carried out on 56 patients with validated FAP for hyperpigmented deformities of the retinal pigment epithelium. Such lesions were observed bilaterally in 29 (52%) patients and unilaterally in eight (14%) patients. Of the 56 patients, 33 showed one or more of the extracolonic expressions related to Gardner syndrome.^[11]

Case Report

A 13-year-old boy was referred to the radiology department from the dental clinic with two hard and painless swellings. One was located at the inferior surface of the right mandible and the other at the left cheek. On examination, there were two fixed, nontender masses of firm consistency and smooth surface; one was located in the inferior surface of the right side of the body of the mandible and the other at the left ramus of the mandible. It does not interfere with mandibular movement. Moreover, there was high-arched palate with crowding of teeth, no intraoral masses, no cervical or facial masses, and no lymph nodes. Some marfanoid features were noticed as moderate thoracic kyphoscoliosis, moderate hypermobility of all joints and skin hyperextensibility, positive thumb and wrist signs. Cardiovascular examination revealed a systolic

murmur in the tricuspid area. Generally, the patient was well, afebrile, with normal vital signs.

X-ray was done and showed rounded radiopaque bony lesion at the inferior surface of the right side of the body of the mandible. It measured about 1 cm, with smooth surface giving picture of osteoma [Figure 1].

CT scan for the skull bone was done for more localization of the osteomas and to identify any other bony lesions in the skull or mandible. It showed a well-defined osteoma measuring 1 × 1.5 cm originating from the inferomedial surface of the right side of the body of the mandible and another osteoma on the left ramus of the mandible measuring about 0.8 cm [Figures 2 and 3].

CT scan abdomen with oral and IV contrast was done, which revealed multiple pedunculated filling defects (polyps) noted in the descending and the transverse colon [Figure 4]. Patient was referred for endoscopy and colonoscopy; upper endoscopy and colonoscopy showed multiple flat tan pink polyps involving the antrum of the stomach, the colon, and terminal ileum ranging in size from 0.3 to 0.5 cm.

Biopsy was taken for histopathological examination, which reported multiple tubular adenomas of colon consistent with FAP—no features of high grade dysplasia were found. Fundoscopy was done, and two patches of hyperpigmentation in the right retina were seen, with normal left retina. Gardner was confirmed, and prophylactic colectomy was done for the patient as the polyps show a high potential for malignant transformation. Excision of osteomas was planned, and, now, he is on regular follow-up. Family members were screened for any features of FAP. Fortunately, no positive result was reported.

As a differential diagnosis, intestinal polyposis syndromes represent different types of FAP, including hereditary-mixed polyposis syndrome, Hamartomatous polyposis syndromes, and other variants such as Turcot syndrome.

Discussion

Early in 1882, Cripps noticed colorectal polyps in a familial setting; later, Dukes reported that adenomas predispose to colonic and rectal carcinomas. In 1932 Nicholas observed the link between desmoid tumors and FAP. In 1951 and 1952 Gardner, Plenk, and Richards reported the association between osteomas, desmoid tumors, epidermoid cysts, and FAP.

Gardner's syndrome is a multisystemic disease with multiple symptoms that are usually evident by the twentieth year of age; but, they may present anytime between 2 months and 70 years. In general, the cutaneous and bone abnormalities develop approximately 10 years prior to polyposis.^[12–15] It is a rare autosomal dominant condition that mainly occurs owing to mutation in the APC tumor suppressor gene located in chromosome 5. It is one variant of FAP, which is characterized by multiple adenomatous intestinal polyps, which inevitably progress to colorectal carcinoma, because Marfan-like conditions occur owing to germline mutations in chromosome 5 as well. Calin *et al.*^[5]

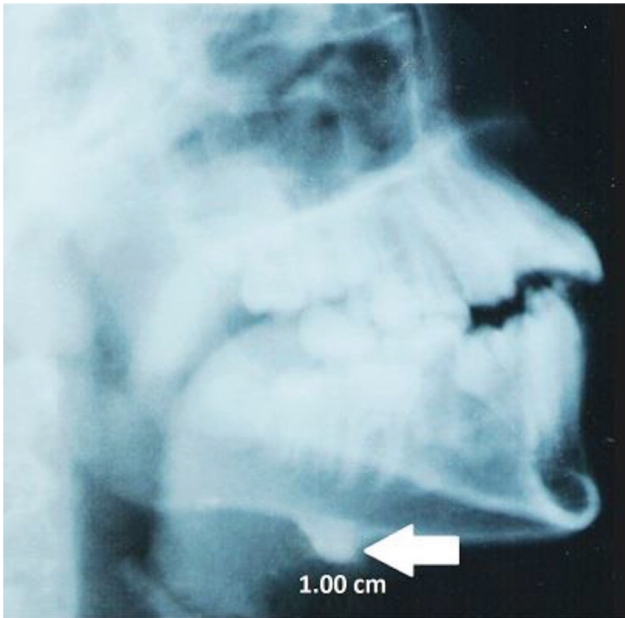


Figure 1: X-ray lateral mandible showing well-defined, rounded, radiopaque bony lesion at the inferior border of the right mandible measuring about 1 cm in diameter.

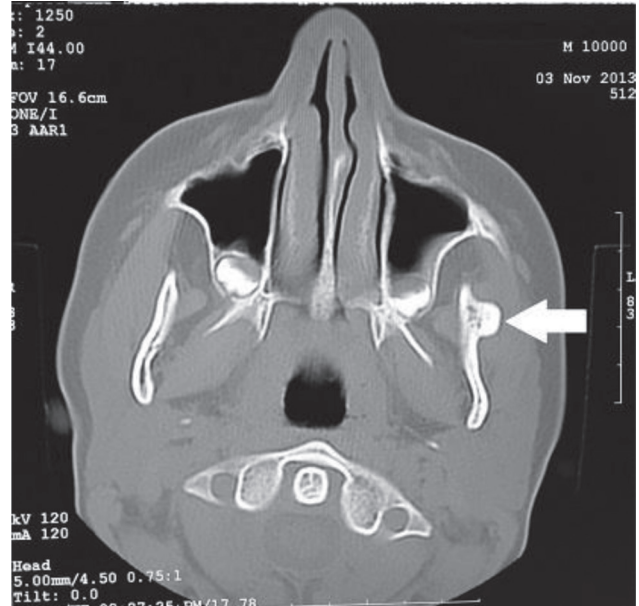


Figure 3: CT scan showing 0.8 cm osteoma originating from the left zygomatic bone.

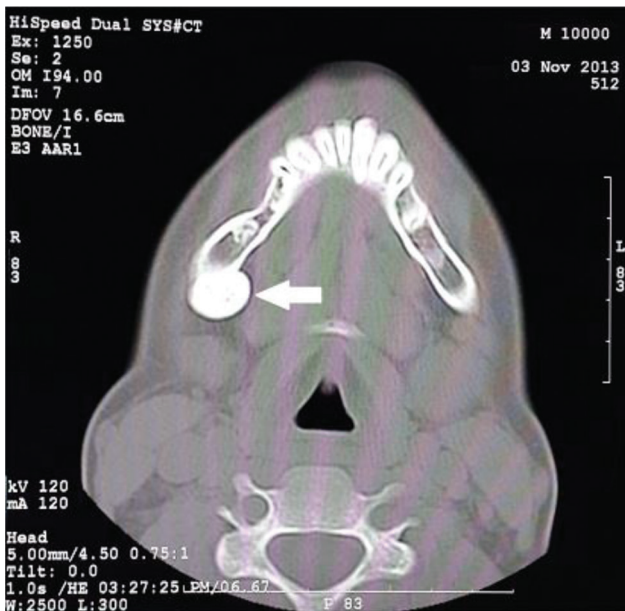

Figure 2: CT scan showing 1 x 1.3 cm, well-defined, rounded osteoma at the inferior surface of the right mandible.

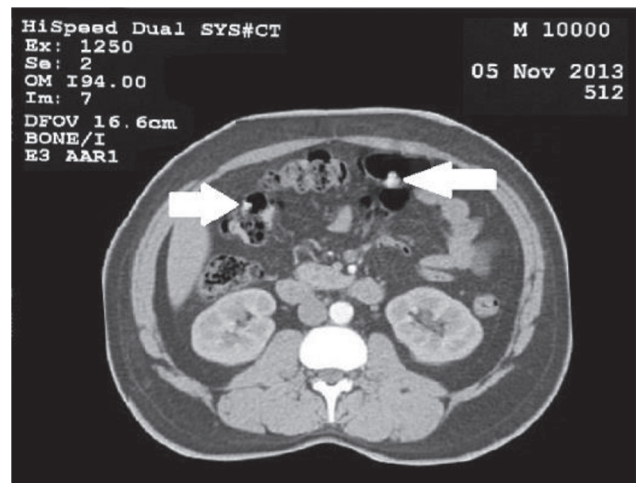


Figure 4: Axial CT scan abdomen with contrast showing multiple colonic polyps.

were the first to report two cases of FAP with several extracolonic abnormalities of mesodermal origin strongly resembling Marfan syndrome. They did conventional cytogenetic analysis on the two cases. On the first case, there was no gross

chromosomal rearrangement on the long arm of chromosome 5, where the APC and FBN2 genes were located. While in the second case, the FAP-causing mutation in the APC gene was found in splice site of exon 4 and was shown to result in a frameshift and a premature termination codon. They proposed that such connective tissue abnormalities might result from germline APC mutations in combination with specific genetic and/or environmental modifying factors. Our case study was in line with their proposition because there were marfanoid-like features noticed on a diagnosed case of FAP.

The colonic polyps of FAP-Gardner's syndrome exhibit a 100% risk of undergoing malignant transformation; consequently, early identification and surgical therapy of the disease are critical.^[14,15]

Conclusion

Chromosomal changes that are responsible of FAP may also lead to marfanoid-like changes, because they are both located in chromosome 5. Our case is the Gardner's syndrome, which is a life-threatening disease, because it holds 100% risk of malignant transformation. It is composed of colonic disorders as colonic polyps which show high potential for malignant transformation and extra colonic disorders such as osteoma, desmoid tumors, and epidermoid cysts which are benign tumors. Fortunately, osteomas and skin manifestations precede polyposis, and this facilitates early diagnosis of Gardner's syndrome and gives chance for rapid prophylactic surgical resection of colonic polyps, which is critical and life-saving for patients with Gardner's syndrome. Our case is a 13-year-old boy; his primary presentation was mandibular osteoma, which facilitated the early diagnosis of his condition after thorough investigations, and rapid lifesaving prophylactic colectomy was done for him.

References

- Davies DR, Armstrong JG, Thakker N, Horner K, Guy SP, Clancy T, et al. Severe Gardner syndrome in families with mutations restricted to a specific region of the APC gene. *Am J Hum Genet* 1995;57(5):1151–8.
- Panjwani S, Bagewadi A, Keluskar V, Arora S. Gardner's Syndrome. *J Clin Imaging Sci* 2011;1:65.
- M.H. Nieuwenhuis, M.H. Nieuwenhuis. Correlations between mutation site in APC and phenotype of familial adenomatous polyposis (FAP): a review of the literature. *Crit Rev Oncol Hematol* 2007;61(2):153–61.
- Groden J, Thliveris A, Samowitz W, Carlson M, Albertsen H, Joslyn G, et al. Identification and characterization of the familial adenomatous polyposis coli gene. *Cell* 1991;66(3):589–600.
- Calin G, Wijnen J, van der Klift H, Ionita A, Mulder A, Breukel C, et al. Marfan-like habitus and familial adenomatous polyposis in two unrelated males: a significant association? *Eur J Hum Genet* 1999;7(5):609–14.
- Gray JR, Davies SJ. Marfan syndrome. *J Med Genet* 1996;33(5):403–8.
- Putnam EA, Zhang H, Ramirez F, Milewicz DM. Fibrillin-2 (FBN2) mutations result in the Marfan-like disorder, congenital contractual arachnodactyly. *Nat Genet* 1995;11(4):456–8.
- Gu GL, Wang SL, Wei XM, Bai L. Diagnosis and treatment of Gardner syndrome with gastric polyposis: a case report and review of the literature. *World J Gastroenterol* 2008;14(13):2121–3.
- Gorlin RJ, Pindborg JJ, Cohen MM. *Syndromes of the Head and Neck*, 2nd edn. New York: McGraw-Hill, 1976. pp. 324–8.
- Ascari-Raccagni A, Baldari U, Righini MG. Cutaneous symptoms of Gardner's syndrome. *J Eur Acad Dermatol Venereol* 1999;12:80–1.
- Baker RH, Heinemann MH, Miller HH, DeCosse JJ. Hyperpigmented lesions of the retinal pigment epithelium in familial adenomatous polyposis. *Am J Med Genet* 1988;31(2):427–35.
- Fotiadis C, Tsekouras DK, Antonakis P, Sfiniadakis J, Genetzakis M, Zografos GC. Gardner's syndrome: a case report and review of the literature. *World J Gastroenterol* 2005;11(34):5408–11.
- Nandakumar G, Morgan JA, Silverberg D, Steinhagen RM. Familial polyposis coli: clinical manifestations, evaluation, management and treatment. *Mt Sinai J Med* 2004;71(6):384–91.
- Newman CA, Reuther WL 3rd, Wakabayashi MN, Payette MM, Plavsic BM. Gastrointestinal case of the day. Gardner syndrome. *Radiographics* 1999;19:546–8.
- Cruz-Correa M, Giardiello FM. Diagnosis and management of hereditary colon cancer. *Gastroenterol Clin North Am* 2002;31(2):537–49.
- Butler J, Healy C, Toner M, Flint S. Gardner syndrome—review and report of a case. *Oral Oncology Extra* 2005;41(5):89–92.
- Bilkay U, O. Erdem, C. Ozek, E. Helvaci, K. Kilik, Y. Ertan, T. Gurler. Benign osteoma with Gardner syndrome; review of the literature and report of a case. *J Craniofac Surg* 2004;15(3):506–9.

How to cite this article: Kheiralla OAM, Aedh AI, Babikr WG, Globawe MMA. Case report of unusual presentation of marfanoid features in a 13-year-old boy with Gardner's syndrome. *Int J Med Sci Public Health* 2016;5:1034-1037

Source of Support: Nil, **Conflict of Interest:** None declared.